

Radiological Response and Clinical Outcome in Patients with Femoral Bone Metastases after Radiotherapy

Hideyuki HARADA^{1*}, Hirohisa KATAGIRI², Minoru KAMATA¹, Yasuo YOSHIOKA¹,
Hirofumi ASAKURA¹, Takayuki HASHIMOTO¹, Kazuhisa FURUTANI¹,
Mitsuru TAKAHASHI², Harumi SAKAHARA³
and Tetsuo NISHIMURA¹

Radiotherapy/Bone metastasis/Pathological fracture/Radiological change/Bone healing.

We evaluated the radiological response and clinical outcome in patients with femoral bone metastases after radiotherapy. 102 consecutive patients with femoral metastases without pathological fracture were treated by surgery or radiotherapy between 2002 and 2005. Twelve of them initially treated with surgery were excluded from this study. The remaining 90 patients with 102 lesions underwent radiation therapy as the initial treatment. Twelve patients who died within 30 days by disease progression and 6 who were lost to follow-up were excluded. The remaining 72 patients with 84 lesions including 43 impending fractures were enrolled in this analysis. Radiological changes were categorized into complete response, partial response, no change, and progressive disease based on plain radiograph findings. Pain relief was reviewed for 77 painful lesions. The median radiation dose was 30 Gy. No re-irradiation was performed. 35 lesions (42%) achieved radiological responses median 3 months after radiotherapy. Pain relief was obtained in 36 of 77 lesions (47%). There was no significant correlation between radiological response and pain relief ($P = 0.166$). Eleven lesions eventually required surgery and considered as treatment failure. The treatment failure rate in the radiological progressive disease (PD) group (8/19, 42%) was significantly higher than that in the non-PD group (3/65, 5%) ($P < 0.001$). Among 43 impending fracture lesions, 15 lesions (36%) experienced radiological response and 35 lesions (81%) required no surgical interventions. Our data suggest that radiotherapy can enable metastatic bone healing and avoid surgery in many lesions. However, radiological PD lesions often require surgery after radiotherapy.

INTRODUCTION

The femur is one of the most frequent sites for skeletal metastases. A pathological femoral fracture in a metastatic lesion compromises patients activity and quality of life. Many radiotherapy studies have been reported for bone metastases, and pain control is achieved in 70% to 80% of patients.^{1–3)} However, impending fracture cases were excluded in many trials, because patients with high-risk lesions for pathological fracture should be considered for surgical fixation.^{4–6)} In clinical practice, on the other hand, surgery is not

appropriate in some patients because of the active visceral diseases, multiple bone metastases or poor general condition even with impending fracture. Even in such situations, some of these lesions could be sufficiently healed with recalcification and pain relief was obtained by radiotherapy.

The purpose of this study was to clarify the clinical result of radiotherapy for femoral bone metastases from the point of not only pain relief but also radiological healing and fracture prevention by reviewing the clinical charts and radiographs.

MATERIALS AND METHODS

This retrospective study was approved by the Institutional Review Board at Shizuoka Cancer Center Hospital.

Patient characteristics and selection

From a prospectively maintained database of the Divisions of Radiation Oncology, Proton Therapy and Orthopedic Oncology at Shizuoka Cancer Center Hospital, consecutive

*Corresponding author: Phone: +81-55-989-5222,
Fax: +81-55-989-5783,
E-mail: h.harada@schr.jp

¹Divisions of Radiation Oncology and ²Orthopedic Oncology, Shizuoka Cancer Center, Shimonagakubo 1007, Nagaizumi, Shizuoka, Japan;
³Department of Radiology, Hamamatsu University School of Medicine, Handayama 1-20-1, Higashi-ku, Hamamatsu, Shizuoka, Japan.
doi:10.1269/jrr.09096

102 patients without pathological fracture were identified during September 2002 to December 2005. Usually, a routine plain radiography and bone scan or magnetic resonance imaging study were done in diagnosis. Among them, 12 patients with 12 lesions were considered apparent impending fractures and good candidates for prophylactic surgical fixation. These 12 patients were treated surgically prior to radiotherapy and excluded from this study. Therefore, the remaining 102 lesions in 90 patients were treated with radiotherapy. Among these 90 patients, eighteen were excluded from this study for the following reasons; death within 30 days from the initiation of radiotherapy by disease progression in 12, and loss to follow-up in 6.

The remaining 72 patients with 84 lesions were enrolled in this study. Among them, painful metastases were identified in 77 lesions of 66 patients, and the remaining 7 lesions in 7 patients caused no pain. Additional systemic therapies including chemotherapy, hormonal therapy or administration of bisphosphonate were performed in some patients during or after radiotherapy. Patient characteristics were summarized in Table 1.

Table 1. Patient Characteristics

Gender	
Male	42 (58%)
Female	30 (42%)
Age (year)	
Median	59
Range	31–85
Systemic therapy	
Chemotherapy	18 (25%)
Hormone therapy	12 (17%)
Chemotherapy + Bisphosphonate	9 (13%)
Chemotherapy + Bisphosphonate + Hormone therapy	8 (11%)
Bisphosphonate	5 (7%)
Chemotherapy + Hormone therapy	2 (2%)
Bisphosphonate + Hormone therapy	1 (1%)
None	17 (24%)
Primary sites	
Breast	25 (35%)
Lung	15 (21%)
Prostate	11 (15%)
Liver, thyroid, kidney	6 (8%)
Other	15 (21%)

Median follow-up duration was 5 months (range; 1–28 months). We retrospectively analyzed radiological response, impending and actual fracture after radiotherapy, pain relief and survival for these patients.

Radiotherapy

All radiation treatment plans were conducted using a volumetric computed tomography based three-dimensional treatment planning system. Planning target volume was defined as a tumor volume with a surrounding margin of at least 2–3 cm. Radiotherapy was administered with high-energy photons of 6, 10 or 18 MV from a linear accelerator by anterior-posterior opposed beam arrangement. Radiotherapy regimens ranged from 20 Gy in 5 fractions to 40 Gy in 20 fractions and median radiation dose was 30 Gy in 10 fractions. The distribution of lesions by dose and fractionation is as follows; 40 Gy in 20 fractions: 8 lesions (10%), 39 Gy in 13 fractions: 27 lesions (32%), 36 Gy in 12 fractions: 1 lesion (1%), 33 Gy in 11 fractions: 1 lesion (1%), 30 Gy in 10 fractions: 41 lesions (49%), 20 Gy in 5 fractions: 6 lesions (7%). No re-irradiation was performed.

Radiological evaluation

Initial pattern of bone destruction and radiological responses of the femur were evaluated on plain radiographs. Skeletal metastases present as osteolytic, sclerotic or even normal lesion on plain radiographs. Among 84 lesions, 39 were lytic, 32 were lytic and sclerotic (mixed), 7 were sclerotic, and 6 were undetectable on plain radiograph. Particularly, 6 lesions which were apparently undetectable on plain x-ray were diagnosed by computed tomography or magnetic resonance imaging. There has been no modern consensus as to radiological assessment of skeletal metastasis after radiotherapy. Therefore, we used our original response criteria in this study (Table 2), which are based on initial radiological appearance, recalcification and structural change on plain radiographs revealing bone remodeling. We divided the responses into four categories; complete response (CR), partial response (PR), no change (NC) and progressive disease (PD). For lytic, mixed, and undetectable lesions on plain radiography before radiotherapy, post-radiotherapy radiographic findings including normalization, sclerosis and regression in size were considered favorable findings.

On the other hand, for sclerotic lesions, normalization and regression in size were considered favorable findings. The representative radiographs are shown in Fig. 1.

An impending fracture was evaluated according to the Mirels scoring system⁶⁾ (Table 3). As proposed by Mirels, a cut-off point for impending fracture between 8 and 9 was chosen. Among 84 lesions, 43 lesions were scored more than 8 and categorized as an impending fracture.

Initial and every follow-up plain radiographs were independently assessed by a radiologist and an orthopedic oncologist. When evaluations differed between two observers, the

Table 2. Radiological response criteria

Response Type	Initial plain radiography pattern			
	Sclerotic	Mixed	Lytic	Undetectable
Complete response	Normalization Complete filling in	Normalization Complete filling in	Normalization	CompleteSclerosis
Partial response	Regression in size Partial filling in Regression in size	Sclerotic rim Partial filling in Regression in size	Sclerotic rim Partial filling in	Sclerotic rim
No change	No change	No change	No change	No change
Progressive disease	Increase in size	Increase in size	Increase in size	Appearance of lytic lesion

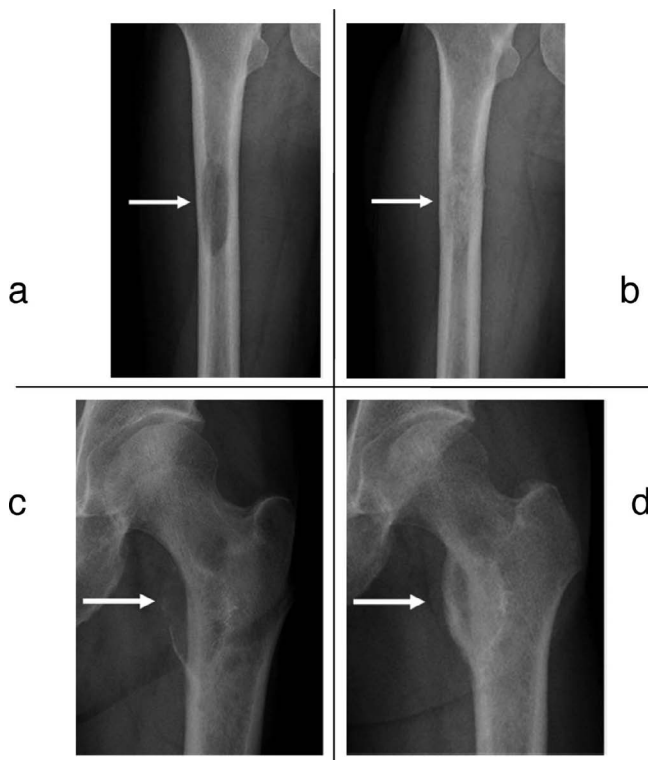


Fig. 1. Representative Radiographs. a) Radiograph before radiotherapy showed lytic metastasis. b) After radiotherapy, it appeared to be a 'complete filling in' and was categorized as CR. c) Radiograph before radiotherapy showed lytic metastasis. d) After radiotherapy, it appeared to be a 'sclerotic rim' and was categorized as PR.

less favorable evaluation was adopted. Therefore, in order to achieve CR, both of the observers had to classify the lesion as CR. As for PR, both observers were required to evaluate either CR or PR.

Assessment of pain relief

We assessed pain relief within one month after completion of radiotherapy. Pain was recorded according to a

Table 3. Scoring system of impending fractures by Mirels

	Score*		
	1	2	3
Site	-----	Shaft/distal femur	Proximal femur
Pain†	Mild	Moderate	Severe
Lesion‡	Blastic	Mixed	Lytic
Size	< 1/3	> 1/3, < 2/3	> 2/3

* Each lesion is assessed on four variables.

† If there was no pain, the pain score was recorded as 1.

‡ If skeletal metastases present as normal lesion on plain radiographs, the lesion score was recorded as 1.

patient complaints. Pain relief was simply classified into three categories; improved, stable and progressive because of a potentially confounding effect of pain medications for multiple bone metastases or visceral disease. An improved lesion was defined as pain decreased without concomitant increase in analgesic intake. A progressive lesion was defined as pain increase. A lesion which was not classified as either improved or progressive was defined as stable.

Treatment failure

Lesions required surgery after radiotherapy was defined as treatment failure. It contains both actual fracture and lesions considered as virtual fracture with apparent disappearance of bone density and increasing severe pain.

Statistical analysis

The Kaplan-Meier analysis⁷⁾ was used to estimate survival probabilities and median survival time. In a case with multiple lesions irradiated, the duration of survival was calculated from the start of radiotherapy for the first lesion. Kappa coefficient was used to determine whether there was significant inter-observer agreement between the radiological response rates. Fisher's exact probability (one-tailed test) was used to determine whether there was significant differ-

ence in actual fracture rate and treatment failure rate. A *p*-value of less than 0.05 was considered to be statistically significant. All statistical analyses were performed by application of Dr. SPSS II for Windows (SPSS Inc., Chicago, IL).

RESULTS

Radiological response

Eight lesions (10%) achieved radiological CR and 27 lesions (32%) achieved radiological PR on the plain radiographs. The overall best response rate (CR + PR) was 42% (35 out of 84 lesions). Thirty lesions were classified as NC. Nineteen lesions (23%) were classified as radiological PD in follow-up radiographs. In impending fracture lesions, 15 of 43 lesions (35%) showed a radiological response.

At 3, 6, and 12 months after radiotherapy, 49 patients with 57 lesions, 32 patients with 38 lesions, and 15 patients with 18 lesions were alive and evaluable, respectively. The radiological response rates of the surviving patients at 3, 6, and 12 months from the initiation of radiotherapy were 30%, 45%, and 50%, respectively. The median interval from the start of radiation therapy to the appearance of a favorable radiological response (CR or PR) was 3 months (range, 1–13 months). The assessment of our original criteria demonstrated inter-observer agreement (Kappa coefficient = 0.463, *P* < 0.01). Administration of systemic therapy (chemotherapy or hormonal therapy), bisphosphonate and primary site are significantly correlated with favorable radiological response (Table 4).

In 35 radiological responding lesions, 30 had been free

from local radiological progression until death or last follow-up visit with a median period of 10 months (2–28 months). The remaining 5 lesions showed regrowth of local disease on plain radiographs after the median duration with response of 6 months (range, 4–9 months).

Treatment failure

Eleven lesions (13%) eventually required surgery and considered as treatment failure. Among them, 8 patients with 8 lesions showed actual fracture. Seven of eight fractured lesions had been initially categorized as impending fracture, and only one of eight lesions as no impending fracture. Fracture rate in impending fracture group (7 of 43; 16%) was significantly higher than that in no impending fracture group (1 of 41; 2%) (*P* = 0.034). The rest of 3 patients with 3 lesions showed apparent disappearance of bone density with increasing severe pain and were considered as fracture virtually. These lesions required surgery after a median duration of 3 months (range: 0–11 months) from the start of radiotherapy (Table 5). There was a significant difference in the treatment failure rate between the radiological PD (8 of 19, 42%) and radiological non-PD group (3 of 65, 5%), (*P* = 0.001). On the other hand, 38 lesions (93%) out of no impending fracture group and 35 lesions (81%) out of impending fracture group required no surgical interventions.

In 10 lesions among 11 surgically managed lesions, pathological examination of the irradiated bone was performed. No viable tumor cell but degenerating bone fragment was found by pathological examinations in 2 lesions, while the remaining 8 cases evidenced viable tumor cells.

Pain relief

Seven patients had no pain before the initiation of radiotherapy. In the remaining 77 lesions, 36 lesions (47%) were classified as improved, 36 lesions (47%) as stable, and 5 lesions (6%) as progressive. There was no correlation between radiological response and pain relief (*P* = 0.166).

Survival

The overall median survival was 7 months (95% confidence interval was 4–9 months). The 6- and 12-month esti-

Table 4. Univariate analyses for radiological response

	Response Rate	<i>P</i> value
Systemic therapy*		
Yes/No	50%/23%	0.001
Bisphosphonate		
Yes/No	59%/31%	0.010
Impending fracture		
Yes/No	36%/48%	0.301
Radiation dose		
> 33 Gy/ 33 Gy <	33%/53%	0.074
Primary sites		
Breast	47%	
Lung	65%	
Prostate	42%	
Thyroid, Kidney, Liver	0%	
Other	28%	0.033

* Chemotherapy or Hormone therapy

Table 5. Number of treatment failure divided by radiological response

	Radiological response		
Initial assessment	Non-PD	PD	Total
Impending fracture	2/30 (7%)	6/13 (54%)	8/43 (19%)
No impending fracture	1/35 (1%)	2/6 (33%)	3/41 (7%)
Total	3/65 (5%)	8/19 (42%)	11/84 (13%)

Abbreviation: PD = progressive disease

mated survival was 52% and 38%, respectively.

DISCUSSION

Although there were many reports concerning pain relief of radiotherapy, other therapeutic effects such as prevention of pathological fractures and radiological healing have not been well documented. In this study, 42% of irradiated lesions showed a radiological response. Without metastatic cells, bone resorption and formation are balanced and maintained dynamically. Metastatic bones present as osteolytic, osteoblastic or mixed, and are caused by a disorder of this mechanism due to metastatic cancer cells. Thus, radiological remodeling of the irradiated bone means the favorable therapeutic effect of radiotherapy. In addition, there is a clear relationship between reduced bone density and increased fracture risk.⁸⁾ Therefore, it is important for oncologists to radiologically assess bone healing of the radiotherapy. Previously there were some response criteria for skeletal metastasis, but they do not meet the needs of oncologists and use in practice.⁹⁻¹¹⁾ Recently, Hamaoka *et al.*¹²⁾ proposed response criteria based on structural changes for metastatic bone from breast cancer. Their criteria cover not only local changes but also the findings of whole-body skeletal scintigram. If a new lesion appears, the criteria categorize progressive disease regardless of the local response. Thus, although Hamaoka's criteria are appropriate to assess the therapeutic effect by systemic chemotherapy, they are not appropriate for the assessment of radiotherapy. Therefore, we used original criteria in this study based on initial radiological appearance, recalcification and size change by plain radiographs.

There are more sensitive imaging modalities such as computed tomography, magnetic resonance imaging or positron emission tomography. In addition, several reports have used computed-tomography to assess the therapeutic effect of skeletal metastasis.¹³⁻¹⁵⁾ In the present study, we evaluated the response with plain radiography because: 1) The cost of plain radiography is far lower than other diagnostic modalities, and plain radiography seems most convenient. 2) Plain radiography is suitable for evaluating impending fractures and pathological fractures. 3) Structural change of the femoral bone is easier to assess by plain radiography than axial bones.

Matsubayashi *et al.*¹⁶⁾ reported that recalcification following irradiation confirms the success of the treatment. In the majority of radiological responders (29 of 35) in this study, additional systemic therapy was administered during or after radiotherapy. It is considered that the systemic therapy may have added a local anti-tumor effect. Another explanation is that the patients with systemic therapy could have survived longer than the patients without systemic therapy, so the chance of recalcification or favorable structural change would have been increased during their prolonged remaining

lifetime. In fact, the longer the follow-up duration, the better the response rates observed.

In 54% of radiological responders (19 of 35), bisphosphonate was administered during or after radiotherapy. Bisphosphonate is now becoming the treatment of choice for skeletal metastasis, because of its ability to inhibit osteoclast-mediated bone destruction.¹⁷⁾ Recent research reported evidence from preclinical research showing that bisphosphonates also exhibit antitumor activity, both in vitro and in vivo.¹⁸⁾ Our study also supported the efficacy of bisphosphonate in the management of patients with skeletal metastasis.

In this study, 11 of 84 lesions (13%) eventually required surgery due to fractures. Fracture rate in this cohort is comparable to previous published data.¹⁹⁾ The treatment failure rate in the radiological PD group was significantly higher than in the radiological non-PD group. Both fractured patients in the non-PD group (one CR and one NC) showed no viable tumor cells by pathological examinations. Matsubayashi *et al.*¹⁶⁾ described the process of remodeling. Once a lesion has been mineralized to a maximum, it begins to be remodeled and to regain its normal bone structure. The course of remodeling takes nearly one year. Radiotherapy was considered effective in these cases but fracture occurred before the remodeling had been completed. Another explanation is that osteoporosis, bone-marrow fibrosis or osteonecrosis which occurred due to radiotherapy decreased bone flexibility and fractures occurred.²⁰⁾

Generally speaking, metastatic lesions with a high risk of fracture often require surgical stabilization, although low-risk lesions can be treated by radiotherapy with or without systemic therapy. In the no impending fracture group, treatment failure occurred in only 7% (3 of 41) of the patients. Therefore, we conclude that most of the patients without impending fracture are adequately managed by radiotherapy, and should be treated accordingly.

In this study, patients with poor general condition or poor performance status were treated by conservative treatment with radiotherapy even with an impending fracture. Our study revealed that 35% of the lesions with the impending fracture, responded to radiotherapy and only 19% (8 lesions) of the lesions required surgery. Thus, the risk of pathological fracture could be decreased by radiotherapy, and surgery was not always necessary for all impending fracture patients. The appropriate radiotherapy and physiotherapy would be an alternative treatment in these situations. On the other hand, lesions with impending fracture and radiological PD on follow-up radiographs had a fracture rate of as high as 46% (6 of 13). If the general condition is sufficient for surgery, these patients should be treated by prophylactic internal fixation.

A previous publication reported that radiological recalcification is not correlated to pain relief.¹⁴⁾ Also, in this cohort, there was no correlation between radiological response and pain relief. Therefore, it is important to assess radiological response and pain relief independently.

In conclusion, our data suggest that radiotherapy can enable bone healing and avoid surgery for femoral metastases during their remaining lifetime by radiotherapy. Initial and follow-up radiological assessments correlated fractures and were useful in predicting fracture.

ACKNOWLEDGEMENTS

Financial support for this study was provided by Re-union of Department of Radiology, Hamamatsu University School of Medicine. We wish to thank Masashi Mizumoto, Tatsuya Takagi, and Hideki Murata who helped to draft the manuscript.

REFERENCES

1. The Bone Pain Trial Working Party. (1999) 8 Gy single fraction radiotherapy for the treatment of metastatic skeletal pain: randomized comparison with a multifraction schedule over 12 months of patient follow-up. *Radiother Oncol.* **52**: 111–121.
2. Steenland, E., Leer, J., Van Houwelingen, H., Post, W. J., van den Hout, W. B., Kievit, J., Haes, H., Martijn, H., Oei, B., Vonk, E., Van der Steen-Banasik, E., Wiggenraad, R. J. G., Hoogenhout, J., Wárlám-Rodenhuis, C., Van Tienhoven, G., Wanders, R., Pomp, J., Van Reijn, M., Van Mierlo, T. and Rutten, E. (1999) The effect of a single fraction compared to multiple fractions on painful bone metastases: a global analysis of the Dutch Bone Metastasis Study. *Radiother Oncol.* **52**: 101–109.
3. Wu, S. Y., Wong, R., Johnston, M., Bezjak, A. and Whelan, T. (2003) Meta-analysis of dose-fractionation radiotherapy trials for the palliation of painful bone metastases. *Int. J. Radiat. Oncol. Biol. Phys.* **55**: 594–605.
4. Beals, R. K., Lawton, G. D. and Snell, W. E. (1971) Prophylactic internal fixation of the femur in metastatic breast cancer. *Cancer.* **28**: 1350–1354.
5. Ryan, J. R., Rowe, D. E. and Saliccioli, G. G. (1976) Prophylactic internal fixation of the femur for neoplastic lesions. *J. Bone. Joint. Surg.* **58**: 1071–1074.
6. Mirels, H., Metastatic disease in long bones. (1989) A proposed scoring system for diagnosing impending pathological fractures. *Clin. Orthop.* **249**: 256–264.
7. Kaplan, E. L. and Meier, P. (1958) Nonparametric estimation from incomplete observations. *J. Am. Statist. Assoc.* **53**: 457–481.
8. Harrington, K. D. (1986) Impending pathologic fractures from metastatic malignancy: evaluation and management. *Instr. Course. Lect.* **35**: 357–381.
9. Therasse, P., Arbuck, S. G., Eisenhauer, E. A., Wanders, J., Kaplan, R. S., Rubinstein, L., Verweij, J., Van Glabbeke, M., Van Oosterom, A. T., Christian, M. C. and Gwyther, S. G. (2000) New guidelines to evaluate the response to treatment in solid tumors: European Organization for Research and Treatment of Cancer, National Cancer Institute of the United States, National Cancer Institute of Canada. *J. Natl. Cancer. Inst.* **92**: 205–216.
10. Hayward, J. L., Carbone, P. P., Heusen, J. C., Kumaoka, S., Segaloff, A. and Rubens, R. D. (1977) Assessment of response to therapy in advanced breast cancer. *Br. J. Cancer.* **35**: 292–298.
11. Miller, A. B., Hoogstraten, B., Staquet, M. and Winkler, A. (1981) Reporting results of cancer treatment. *Cancer.* **47**: 207–214.
12. Hamaoka, T., Madewell, E. J., Podoloff, A. D., Hortobagyi, G. N. and Ueno, N. T. (2005) Bone imaging in metastatic breast cancer. *J. Clin. Oncol.* **22**: 2942–2954.
13. Crone, M. W. and Spielmann, R. P. (1987) Quantification of recalcification of irradiated vertebral body osteolyses by dual-energy computed tomography. *Eur. J. Radiol.* **7**: 1–5.
14. Koswig, S. and Budach, V. (1999) Remineralization and pain relief in bone metastases after different radiotherapy fractions (10 times 3 Gy vs. 1 time 8 Gy). A prospective study. *Strahlenther Onkol.* **175**: 500–508.
15. Edward, C., Lori, H., Joel, R., Chow, E., Holden, L., Rubenstein, J., Christakis, M., Sixel, K., Vidmar, M., Finkelstein, J., Hayter, C., Loblaw, A., Wong, R., Szumacher, E. and Danjoux, C. (2004) Computed tomography (CT) evaluation of breast cancer patients with osteolytic bone metastases undergoing palliative radiotherapy - a feasibility study. *Radio Oncol.* **70**: 291–294.
16. Matsubayashi, T., Koga, H., Nishiyama, Y., Tominaga, S. and Sawada, T. (1981) The reparative process of metastatic bone lesions after radiotherapy. *Jpn. J. Clin. Oncol.* **11**(Suppl.): 253–264.
17. Hilner, B. E., Ingle, J. N., Chlebowski, R. T., Gary, C. J. G., Janjan, Y. N., Cauley, J. A., Blumenstein, B. A., Albain, K. S., Allan, L. and Susan, B. (2003) American Society of Clinical Oncology 2003 update on the role of bisphosphonates and bone health issues in women with breast cancer. *J. Clin. Oncol.* **21**: 4042–4057.
18. Clezardin, P., Ebetino, F. H. and Fournier, P. G. J. (2005) Bisphosphonates and cancer-induced bone disease: Beyond their antiresorptive activity. *Cancer Res.* **65**: 4971–4974.
19. Van der Linden, Y. M., Dijkstra, P. D., Kroon, H. M., Lok, J. J., Noordijk, E. M., Leer, J. W. H. and Marijnen, C. A. M. (2004) Comparative analysis of risk factors for pathological fracture with femoral metastases. *J. Bone. Joint. Surg. Br.* **86-B**: 566–573.
20. Massin, P. and Duparc, J. (1995) Total hip replacement in irradiated hips. A retrospective study of 71 cases. *J. Bone. Joint. Surg. Br.* **77**: 847–852.

Received on August 19, 2009

Accepted on September 28, 2009

J-STAGE Advance Publication Date: November 23, 2009